

Inadequate Medication Side Effects in Psychiatric Pathology

CRISTINA FURNICA¹, MARIA-MAGDALENA LEON CONSTANTIN^{1*}, RALUCA OZANA CHISTOL^{1,2}, ANISIA-IULIANA ALEXA^{1*}, STEFAN CONSTANTIN^{3*}, GRIGORE TINICA^{1,2}

¹ Grigore T. Popa University of Medicine and Pharmacy of Iasi, Faculty of Medicine, 16 Universitatii Str., 700115, Iasi, Romania

² Institute of Cardiovascular Diseases of Iasi, 50 Carol I Blvd., 700503, Iasi, Romania

³ Gheorghe Asachi Technical University of Iasi, Electrical Engineering and Applied Informatics Faculty, 21- 23 D. Mangeron Blvd., 700050, Iasi, Romania

Atypical antipsychotic drugs are the first-line of therapy in adult schizophrenia but their effects in children and adolescents have not been well understood. In the current paper there is presented a case of early-onset schizophrenia (EOS) with complex prodromal symptoms for 6 months prior to the acute psychotic episode, followed by an aggravation of the condition with a suicidal attempt secondary to inadequate medication with a dopamine antagonist and a dopamine partial agonist. The patient finally responded to aripiprazole monotherapy with lack of psychiatric symptoms and improvement of social integration for over a year. In our opinion, a multidisciplinary approach involving the research of biochemical interactions between antipsychotic drugs may allow a better understanding of mental diseases, which in turn will contribute to the establishment of the most appropriate diagnostic and therapeutic scheme.

Keywords: dopamine antagonist, dopamine partial agonist, aripiprazole, olanzapine, biochemical interactions, atypical antipsychotics

Neurons in schizophrenic patients secrete greater amounts of dopamine ($C_8H_{11}NO_2$), norepinephrine ($C_8H_{11}NO_3$), and epinephrine ($C_9H_{13}NO_3$) — three neurotransmitters commonly linked to a range of psychiatric disorders. In a normal brain, virtually all dopamine is converted to norepinephrine by dopamine- β -hydroxylase (fig. 1). In a schizophrenic brain, there is a reduced synthesis of norepinephrine or an aberrant formation of dopamine- β -hydroxylase resulting in only an incomplete conversion. Hence, nervous impulses trigger the release of both dopamine and norepinephrine in the synaptic cleft [1, 2].

Schizophrenia, one of the most devastating mental disorders, is distinguished by intrusive voices (auditory hallucinations) that may frequently determine the liable individual to form false beliefs (delusions) including those of religious or political significance that could trigger a perceptual anomaly of the reality towards manifest autolytic behavior [3]. Several researches focus on identifying the signs that could predict the early onset of the disease. On the other side, other studies try to establish a connection between brain functional and morphological anomalies, and the positive or negative outcome of this still enigmatic disease [4].

For the treatment of schizophrenia several antipsychotic drugs may be used. In our case, the patient received olanzapine and aripiprazole.

Olanzapine ($C_{17}H_{20}N_4S$) is an atypical antipsychotic medication used in the treatment of schizophrenia and bipolar disorders, and numerous clinical practice guidelines, recommendations of experts and consensus

of scientific societies continue to consider this veteran antipsychotic as a reference neuroleptic in non-responders to other typical or atypical antipsychotics. Olanzapine has a unique profile and is different from other antipsychotic receptor with high affinity to dopamine receptor D4 and relatively low affinity for D1, D2, D3 and D5. As serotonin receptors are concerned, it has a high affinity for 5-HT_{2A} and 5-HT_{2C} and a minimal affinity for 5HT_{1A} and 5-HT₃. Pharmacodynamically, olanzapine is considered a dirty drug since its affinity for muscarinic cholinergic receptors mechanics, antihistamines H1 and adrenergic receptors is high, which is related to many of its undesirable effects: anticholinergic effects, sedation, hypotension, etc. [5].

Aripiprazole ($C_{23}H_{27}Cl_2N_3O_2$) is an antipsychotic agent of choice in patients with schizophrenia, with a different mechanism of action in relation to second-generation antipsychotics. The therapeutic benefit expected with the use of aripiprazole is associated with its different mechanism of action on dopamine-serotonin stabilizing system. Aripiprazole is a partial dopamine agonist that decreases dopamine levels in the mesolimbic tract and increases relative dopamine in mesocortical tract with a subsequent diminishment of negative and cognitive symptoms [6].

Experimental part

The authors present the case of a 17 years old male with early-onset schizophrenia. The subject was adopted at the age of 4 years and no information concerning his biological family medical history was available. The young man registered good scholar performances and had normal

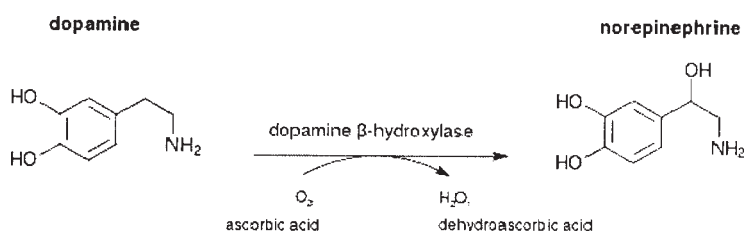


Fig. 1. Dopamine conversion into norepinephrine

* email: leon_mariamagdalena@yahoo.com; anisia_alex@yahoo.com; stefandpr@gmail.com

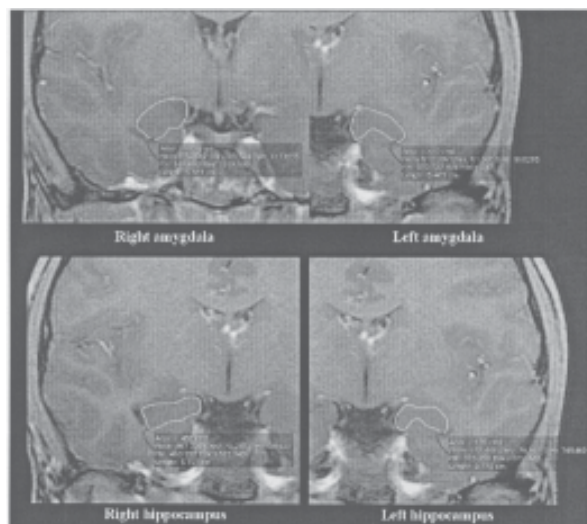


Fig. 2. Area measurements for amygdala and hippocampus

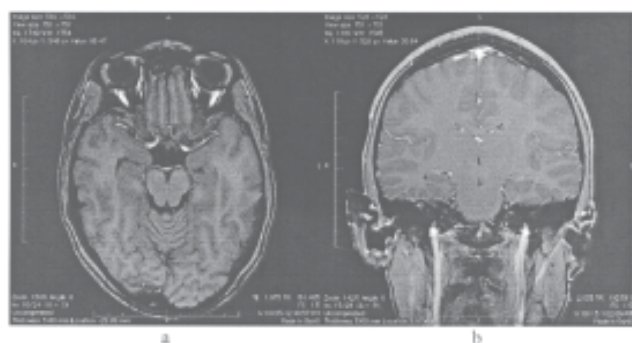


Fig. 3. Visible left-right asymmetry of hippocampus, amygdala (a) and superior temporal gyrus (b)

social skills until 6 months prior to the acute episode, when his adoptive parents noticed a change of mood, defined as a so-called "bad behaviour" with severe decline in school performance. The caregivers addressed the patient to Socola Psychiatry Hospital for psychiatric investigation.

The psychiatrist interviewed both the patient and his caregivers. His adoptive parents signaled mood disorders with pronounced desire of isolation, bizarre behavior, and withdrawal from social activities, variation in affective responses and an increased hostility towards his adoptive family. According to his adoptive parents, school teachers also complained about his loose of interest in school activities, poor motivation and an estate of daydreaming. Being questioned by his caregivers about his attitude towards school, the young man offered no explanation, and accused headaches and stomachaches with any apparent cause.

At the initial psychiatric interview, the patient appeared non-emphatic, with a self-deprecating humor, avoided eye contact, showed flatness of affect, apathy, lack of insight, and hypominia. He complained about having headaches, sleep disturbances and auditory mystic hallucinations, experiencing feelings of unhappiness and persecution, loneliness, interest lost in almost all activities for the last 6 months with no declared suicidal intention.

According to DSM-IV criteria, the patient was diagnosed with a first episode of schizoid psychosis. Treatment with an association of clozapine and aripiprazole was started and cognitive behavioral therapy was indicated, the patient being discharged with a good symptomatic evolution.

Three months after treatment onset, the young man attempted suicide by using narcotics overdose. The parents found him unconscious and called the national emergency number. He was taken to the emergency room and fully

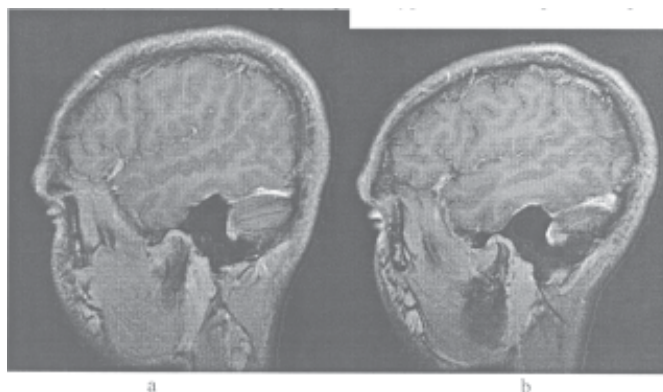


Fig. 4. Superior temporal gyrus asymmetry in sagittal plane (a – right, b-left)

recovered with specific toxicological treatment.

Due to recurrence of headaches, the parents addressed him to a neurologist who indicated a brain MRI in order to exclude subjacent organic anomalies. Part of the neurologic evaluation, the tourniquet test was performed in order to identify a latent hypocalcemia potentially induced by antipsychotic drugs.

Brain MRI was performed at Arcadia Medical Imaging Center, Iasi, Romania on a Philips Achieva 1.5 T machine. The hippocampus and amygdala were delineated on the magnified 3D coronal post-contrast T1 sequence according to the Joint EADC-ADNI Harmonized Protocol [7]. Hippocampal and amygdalian areas were added and multiplied by section thickness in order to calculate their volume (fig. 2).

The superior temporal gyrus (STG) was traced on the 3D coronal post-contrast T1 sequence in a cranio-caudal plane from the first slice where it was visible to the central fissure. The superior temporal sulcus represented the inferior border, and the circular sulcus, the medial border. Volume of the superior temporal gyrus was calculated using the same method as for the hippocampus.

Results and discussions

Results of image analysis revealed a left-right asymmetry of superior temporal gyrus, hippocampus and amygdala, with a visible loss of volume on the left side later confirmed by morphometric measurements (figs. 3, 4).

After being discharged from the hospital and undergoing the MRI examination, the young patient addressed the psychiatric again for treatment reevaluation. Clozapine was removed from the treatment scheme, and aripiprazole was indicated as a monotherapy 22.5 mg/day with lack of psychiatric symptoms and improvement of social integration for over a year.

Prodromal signs that include social isolation and withdrawal, impairment in role function, odd behavior in ideas, and blunted affect often precede the first psychotic episode of schizophrenia [8, 9].

The symptoms of the non-psychotic period are defined as residual or negative symptoms because they reflect the absence of normal social and interpersonal interaction and include social withdrawal, loss of motivation and initiative, apathy, slowness of thought and action, poverty of cognitive processes and speech, emotional blunting [10]. These symptoms are in clear contrast with the abnormalities of a psychotic episode named positive symptoms because they reflect the presence of distinctive behaviors such as delusions, hallucinations and markedly bizarre or disorganized behavior. Due to their persistence, the negative symptoms represent the most unmanageable

part of the illness, partly identified in the current case presentation.

Basically, the pharmacodynamic principles that sustain drug combinations are related to the "complementary" activities of both neuroleptics in different receptor subtypes, which separates the mechanism of action possibly related to the effect on specific symptoms of the drug 1 and drug 2 and further attenuate undesirable effects at high doses appear with either drug separately. In our particular case, the obtained effect was the opposite to the one predicted by pharmacodynamic association principles, and extensive studies have demonstrated the presence of a suicidal risk during treatment with olanzapine [11].

The emergence of new drugs for the treatment of schizophrenia is always covered by a halo of expectations about the therapeutic potential of the drug. However, an already relatively long experience with the use of psychotropic drugs has proved that they all have distinct limitations, which usually only appear or be "discovered" as time passes, through clinical experience, often daunting. Aripiprazole has caused interest among clinicians, since it has a lower affinity for histaminic, muscarinic and adrenergic receptors compared to other antipsychotics. It has a better safety profile, especially as regards weight gain, and its relationship with hyperglycemia, hyperlipidemia and diabetes mellitus [12].

These alterations were reported as uncommon during pre-marketing clinical studies. Given the severe impact of this disease on the productive capacity of people, the need to use this drug in adolescents and young people becomes a real challenge, covered with expectations [13, 14].

Schizophrenia, due to its chronic and potentially damaging character raises the need for effective medication in order to minimize the consequences of the disorder themselves. The fact that in many cases the disorder may have an onset in adolescence complicates the diagnosis, given the characteristics of subjects this age, who often are going through crises inherent in this evolutionary step. The potential use of aripiprazole whose mechanism of action stabilizes the serotonin dopamine system in this clinical entity, may be beneficial in some adolescent patients [14, 15]. There is a need of increased clinical experience with this medication, in order to results that can infer the development of more sustainable conclusions.

Conclusions

The etiopathogenesis of schizophrenia still remain unclear and we believe that new modern research designs that include neuroimaging techniques in their protocol might aid in the definition of the limits and understanding of schizophrenia; for which we still consider nowadays the treatment and diagnostic tools to be inadequate.

Aripiprazole is safe to be used in early onset schizophrenia, has particular properties unfound with other atypical antipsychotics, is associated with minimal metabolic complications and extrapyramidal side effects. As a monotherapy it represents a better option for adolescent patients and could be regarded as first line of treatment. This case report proves the efficiency and safety of aripiprazole in an adolescent patient.

References

- 1.VAN KAMMEN, D.P., KELLEY, M., *Schizophr. Res.*, **4**, no. 2. 1991, p. 173.
- 2.FITZGERALD, P.J., *Psychiatry Res.*, **215**, no. 3, 2014, p. 497.
- 3.SADOCK, B.J., ALCOTT, SADOCK V., RUIZ, P., Kaplan and Sadock's Comprehensive Textbook of Psychiatry., Lippincott Williams and Wilkins, Philadelphia, 2009.
- 4.WRIGHT, I.C., RABE-HESKETH, S., WOODRUFF, P.W., *Am. J. Psychiatry.*, **157**, 2000, p. 16.
- 5.CALLAGHAN, J.T., BERGSTROM, R.F., PTAK, L.R., BEASLEY, C.M., *Clin. Pharmacokinet.*, **37**, no. 3, 1999, p. 177.
- 6.BRENNAN M.D., *Pharmacogenomics.*, **15**, no. 6, 2014, p. 869.
- 7.***, Joint EADC-ADNI Harmonized Protocol (http://www.hippocampal-protocol.net/SOPs/LINK_PAGE/Groups_Protocol/convit-protocol.pdf)
- 8.KRAEPELIN, E., Kraepelin Textbook of Psychiatry 8th ed. RM Barclay, Edinburgh, Livingstone, 1919.
- 9.KANDEL, E.R., SCHWARTZ, J.H., JESSELL, T.M., Principles of Neural Science 3rd ed., Prentice-Hall International Inc., London, 1991.
- 10.CARPENTER, W.T., HEINRICHS, D.W., WAGMAN, A.M., *Am. J. Psychiatry.*, **145**, 1988, p. 578.
- 11.HIEMKE, C., PFUHLMANN, B., *Handb. Exp. Pharmacol.*, **212**, 2012, p. 241.
- 12.Practice Guidelines for the Treatment of Psychiatric Disorders. American Psychiatric Association., Washington, U.S.A., 2002, p. 427.
- 13.SIKICH, L., HAMER, R.M., BASHFORD, R.A., SHEITMAN, B.B., LIEBERMAN, J.A., *Neuropsychopharmacology.*, **29**, no. 1, 2004, p. 133.
- 14.CERNAT, R.I., MOCANU, R.D., POPA, E., SANDU, I., OLARIU, R.I., ARSENE, C., *Rev. Chim.(Bucharest)*, **61**, no. 11, 2010, p. 1130.
- 15.TARKO, L., AVRAM, S., MIHAILESCU, D., *Rev. Chim.(Bucharest)*, **62**, no. 4, 2011, p. 371

Manuscript received: 15.04.2015